

CASE REPORT

Post Surgical Neglected Idiopathic Triple Curve Scoliosis with Neuromuscular and Respiratory Disorders

Rahmatika, Rudy Handoyo, Tanti Ajoie Kesoema

Department of Physical Medicine and Rehabilitation, Faculty of Medicine, University of Diponegoro, Semarang, Indonesia.

ABSTRACT

Introduction: About 75-85% of cases of scoliosis are idiopathic, with unknown cause whose ratio between men and women is 1: 8. In severe scoliosis, many disorders may occur such as muscle imbalance, pain, muscle weakness, degenerative joint disease, decreased cardiovascular capacity, and neurological disorders.

Case Presentation: We reported a 14-year-old boy patient post posterior instrumentation and fusion surgery e.c neglected idiopathic triple curve scoliosis with neuromuscular complications such as weakness in upper and lower limbs causing disruption in hand functions and ambulation disorders, and respiration disorders such as shortness of breath, especially when walking in long-distance or running. The rehabilitation program consisting of exercise in the pool, fine motor exercise, activity of daily living (ADL) exercise, chest expansion exercise, and orthotic administration, which aims to support the recovery of patients to full function as early as possible

Conclusion: After 2 months, the patient showed slight improvement in functional, ambulation, and hand function due to non-routine exercise at the hospital.

Keywords: *Idiopathic Scoliosis, Extremities Weakness, Restrictive Lung*

ABSTRAK

Pendahuluan: Sekitar 75-85% kasus skoliosis adalah idiopatik, dengan penyebab yang tidak diketahui, dan perbandingan antara pria dan wanita adalah 1: 8. Pada skoliosis berat, terjadi banyak gangguan seperti ketidakseimbangan otot, nyeri, kelemahan otot, penyakit sendi degeneratif, penurunan kapasitas kardiovaskular, dan gangguan neurologis.

Presentasi Kasus: Kami melaporkan seorang pasien anak laki-laki berusia 14 tahun pasca operasi dengan teknik instrumentasi posterior dan fusi e.c skoliosis triple curve idiopatik dengan komplikasi neuromuskuler yaitu kelemahan pada anggota gerak atas dan bawah yang menyebabkan gangguan pada fungsi tangan dan gangguan ambulasi, serta gangguan pernapasan seperti sesak napas, terutama saat berjalan jauh dan berlari. Program rehabilitasi yang terdiri dari latihan di kolam, latihan motorik halus, latihan aktivitas sehari-hari, latihan ekspansi rongga dada, serta pemberian ortotik dengan tujuan untuk mendukung pemulihan pasien agar kembali ke fungsional sedini mungkin.

Kesimpulan: Setelah 2 bulan, pasien hanya menunjukkan sedikit peningkatan dalam kemampuan ambulasi dan fungsi tangan karena tidak dapat mengikuti latihan secara rutin di rumah sakit.

Kata Kunci: *Scoliosis Idiopatik, Kelemahan Ekstremitas, Paru Restriktif*

Correspondent Detail:

Rahmatika

Email: tikafitria99@gmail.com

Department of Physical Medicine and
Rehabilitation, Dr. Kariadi General Hospital,
Diponegoro University
Semarang, Indonesia

INTRODUCTION

The Scoliosis Research Society defines scoliosis as curves greater than or equal to 10 degrees, with or without rotatory components.¹ The prevalence of idiopathic scoliosis is reported between 0.3% to 2% of the population.² Based on the magnitude of Cobb's degree, idiopathic scoliosis can be divided into low scoliosis (<25°),

moderate scoliosis (25°-45°) and severe scoliosis (>45°).³ Patient with severe scoliosis of 70° or more not only have the deformity but also can have serious organic health problems, since it is usually progressive with increased cardiac and pulmonary problems, also neuromuscular disorder, which leads to increased mortality.⁴ The main goal of post-operative rehabilitation for severe scoliosis surgery is to restore the patient to its original functional ability and improving strength and confidence. An important issue that needs to be considered when suggesting exercises to the patient during the rehabilitation program is to avoid excessive stress on the healing surgical site and arthrodesis of the spine. Therefore, patients should keep away from exercises that put too much stress on healing regions while performing strengthening and range-of-motion exercises.⁵ Some studies show that the application of respiratory rehabilitation for postoperative scoliosis targeted to increase ventilation may

relieve dyspnea and improves muscle condition and ability to perform an exercise.⁶ Occupational therapy has a role in determines what adaptive equipment and alternative strategies can be utilized to increase ease and independence with ADL's for scoliosis patients.⁷ Finally, returning to social activity and participation is one of the goals of rehabilitation in scoliosis. A study showed that the average time needed to return to school is 10 weeks postoperatively, and 77% of patients had returned to school in 16 weeks postoperatively.⁸

CASE REPORT

A fourteen years old boy was referred from an orthopedic polyclinic to medical rehabilitation polyclinic with post-scoliosis surgery 3 months earlier. In anamnesis we found that the patient was having difficulty walking because of weakness in both legs, he could not run and walk

far, and was limping. The patient's hands are also weak so it is difficult to do activities of daily living such as eating (holding a spoon), holding a plate, drinking from a full glass, but dressing and bathing can be done independently. When he as in elementary school, he had difficulty following the lessons, holding a pen and writing, and because of pain he often did not go to school. The child also often complains of having shortness of breath, especially when doing strenuous activities such as walking in long distances or running so he could not attend sports activities in school. At present, the patient has just graduated from elementary school and has not yet continued his education in junior high school. The wound in the back has already healed and he also did not feel pain anywhere. He still feels ashamed of his condition. The parents noticed an asymmetrical shoulder and hump since he was 2 years old. No family history of scoliosis and no milestone delayed were obtained.

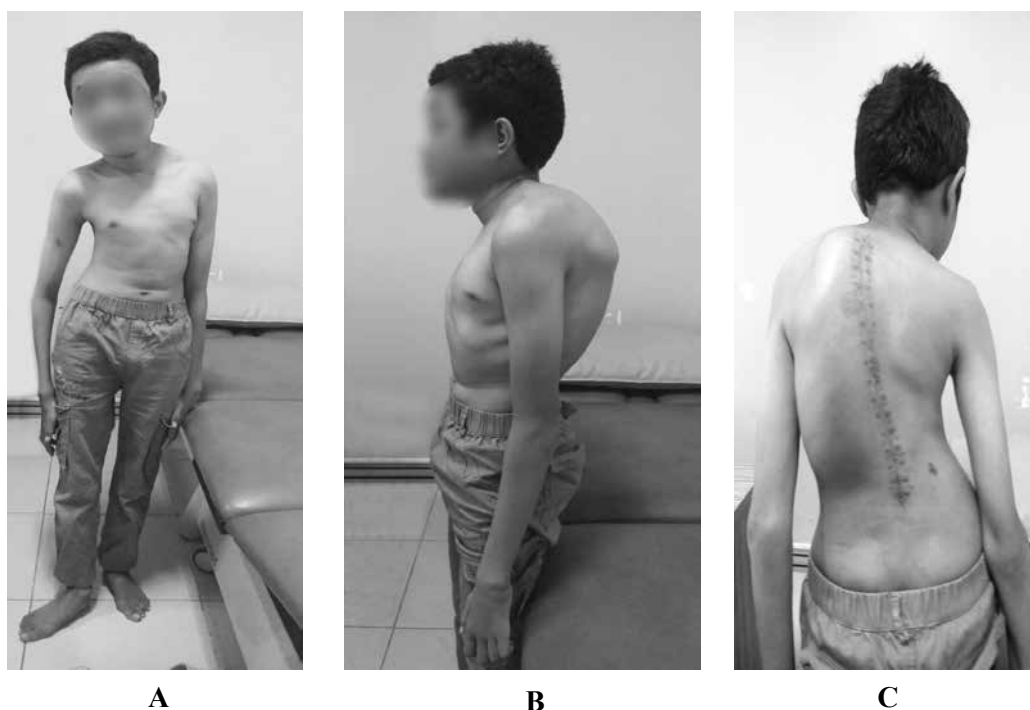


Figure 1. A. Anterior aspect B. Lateral aspect C. Posterior aspect

Physical examination showed the vital sign and internal status is within the normal limit. The body weight is 33 kg and the body height was 143 cm. From posture examination we found that from anterior the head was not in the midline position, asymmetrical in shoulder, nipple, and body arm distance, pelvic obliquity, right ankle valgus, and right knee flexion stiffness, from lateral examination we found forward head, and from posterior, we found hump on the left side and scar. No cafe au lit spot or hairy patch was obtained. From palpation, there was muscle spasm on the concave side, and from the movement, we found a limited range of motion of the trunk. The arm span was 130 cm, and we also obtained leg length discrepancy where apparent length on the right side is 81 cm, left is 80cm; clinical length is 89 cm on right side, left is 85 cm; anatomical length is 71 cm on the right side, left is 70 cm.

Manual muscle testing in the upper extremity have found the strength of elbow flexion, wrist extension, elbow extension were 4 on both sides, while the strength of flexor pollicis longus and abductor digiti minimi muscles were 2 on both sides. There were no pathological reflex, as physiological reflexes were reduced. We also examined the sensibility using cotton and found no numbness and no tingling in the upper extremity. The proprioception function was normal. The hand fine motor function has shown difficulty in spherical grip, hook grip, lumbrical grip, and 3 jaw chuck. There was atrophy in the forearm, thenar and hypothenar muscles in both hands.

Lower extremity examination have shown the strength of hip flexion and knee extension were 4 on both side, while ankle dorsiflexion and long toe extension were 2 on both sides, and ankle plantarflexion were 3 on both side by manual muscle tests. No pathological reflexes were found. The physiological reflexes were reduced. There was atrophy in calf muscles, beside pes cavus in both feet. There were no problem in defecation or urination. Subject walked with limping gait, no heel strikes, and toes touch floor first which showed bilateral feet drop, and stiffness in the right knee. No waddling gait, Gower sign, and pseudohypertrophy of the calf were obtained.

Chest examination obtained chest expansion at the axilla are 66 cm at expiration and 67.5 cm at inspiration; at papilla mammae during expiration is 66 cm and 66.5 cm during inspiration; and at processus xyphoideus during expiration is 63 cm and 63.5 cm during inspiration.

Modified WeeFIM evaluation has found the patient had difficulty in eating, moving to and from the chair, moving to and from the toilet and going up and down the stairs where the patient still had to hold on and needed more time due to weakness in limbs and poor balance. the overall value of Modified WeeFIM is 115. And when we test the patient with 2MWD (2 Minute Walking Distance), he only able to walk for 56 m.

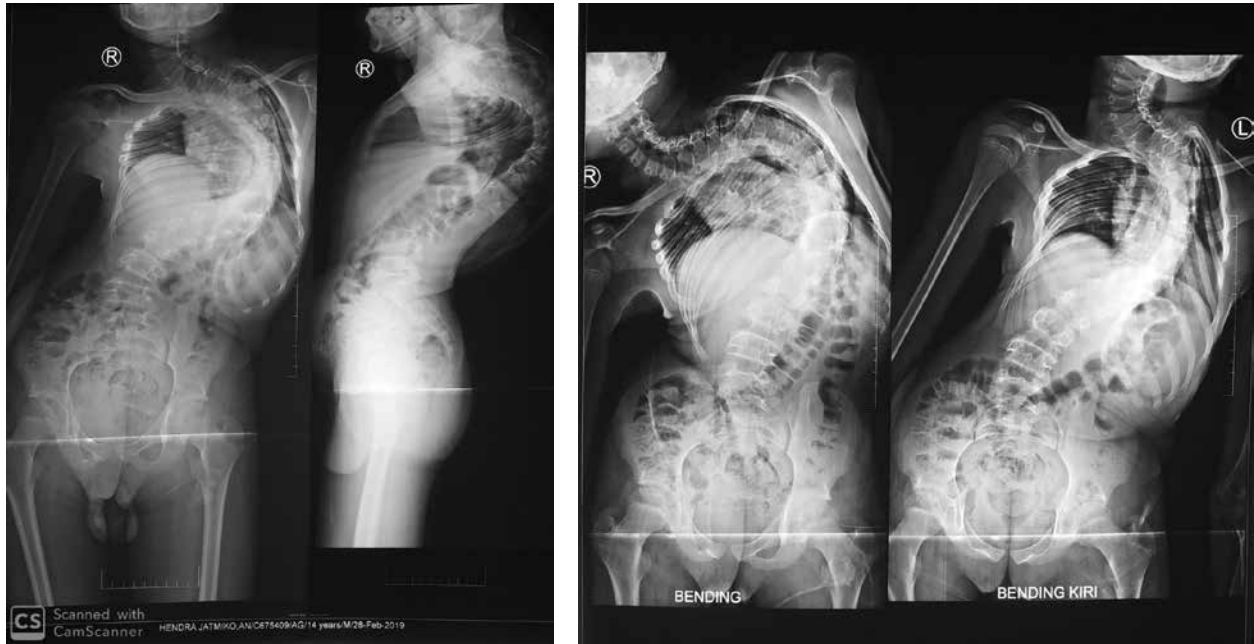

Figure 2. X-ray Scoliosis AP-Lateral and Lateral Bending

From X-ray scoliosis AP-Lateral and Lateral bending we found Th1-L2 vertebrae scoliosis with left convexity (Lippmann Cobb angle $\pm 104^{\circ}$) with the apex at V.Th 8. In the Th1-L2 vertebrae, the bending position to the right we

obtained Lippman Cobb angle $\pm 133^{\circ}$, and the bending position to the left is $\pm 108^{\circ}$. Pedicle V.Th 9 appears to migrate and rotate to the right (grade 3): Nash Moe Method.

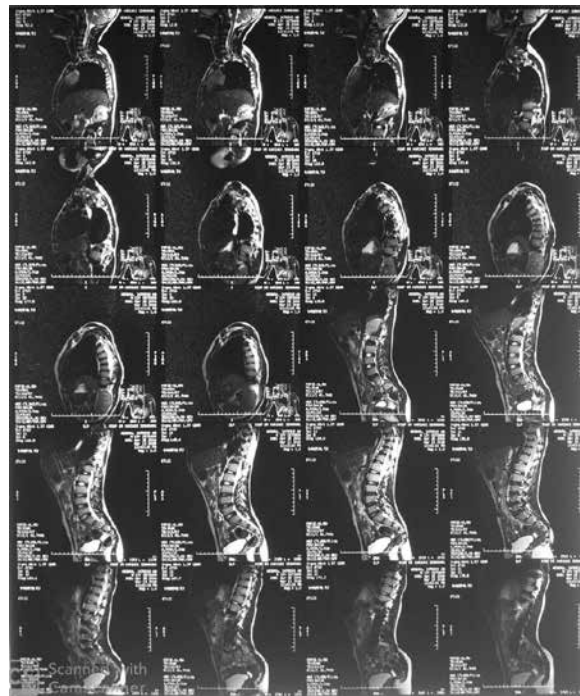


Figure 3. Whole Spine MRI

On whole spine MRI examination without contrast we obtained cervical vertebrae scoliosis with right convexity, thoracic vertebrae scoliosis with left convexity, lumbar vertebrae scoliosis with right convexity, right posterior-lateral bulging of the C7-Th1 intervertebral disc accompanied by narrowing of the right and left neural foramen, posterior central and posterior lateral right and left bulging on the L4-5 and S1-S5 intervertebral discs accompanied by attachment of the thecal sac and narrowing of the left neural foramen.

As for scanogram, we found that the epiphyseal growth plate has not closed yet and there were no genu varus or valgus.

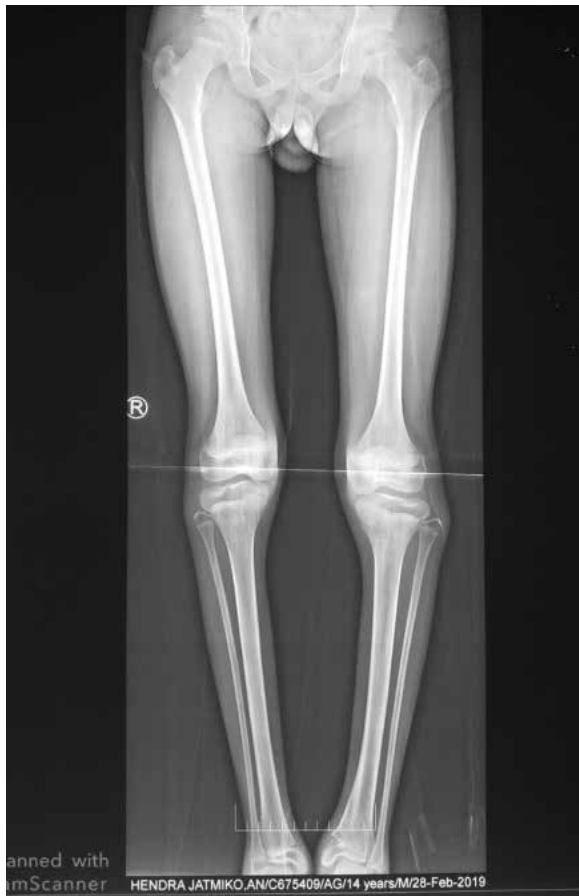

Figure 4. Scanogram

From spirometry, % Pred FVC was 38,6%, % Pred FEV 1 was 41,5% and FEV1/FVC was 108,6%. So we can conclude that the patient had severe restrictive spirometry.

3 months earlier patient underwent surgery with a posterior instrumentation and fusion technique using internal fixation in the form of a pedicle screw and rod system on the corpus V.Th 6-L4.

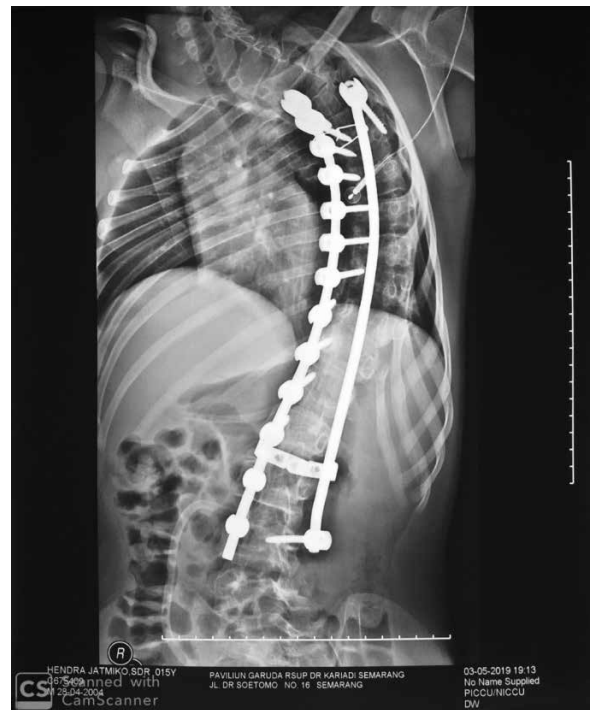

Figure 5. X-ray Thoracolumbal after surgery

From the results of history taking, physical examination, and supporting examination, we found that the patient early-onset idiopathic scoliosis that occurs since the age of 2 years but does not get early intervention.

Working diagnose was myopathy or muscular dystrophy although we did not find a Gower sign, waddling gait or pseudohypertrophy of the calf, and the patient had a normal milestones.

The differential diagnosis of myopathy or muscular dystrophy cannot fully exclude since the patient had no Electromyography, CPK, or genetic evaluation. Some literature also mentions the relationship of progressive scoliosis and weakness in upper and lower extremities with several syndromes. We also had a suspicion that the patient might also have intellectual disability since he had difficulty following lessons at school.

REHABILITATION PROGRAM

The patient came 3 months postoperatively, so we focus on protecting the spine by increasing stabilization by providing exercises to strengthen the core muscles through the drawing in maneuver method. We advised and taught the patient to do the exercise in a supine hook lying position, twice a day with 1-2 sets of 10 repetitions, both as outpatient program and as a home training program.

To strengthen the lower limbs, we provide exercise in the pool to strengthen the hip, knee, and ankle joint and strengthening the limbs became our long-term goal. Exercise in the pool can also reduce pain, improve ROM, and balance so that the patient's ability would improve, and it was done twice a week. Since the patient had severe restrictive lung, the water height should be limited to the umbilical level only. We gave exercise in the pool twice a week, 12-13 Borg scale (low-moderate), for 30 minutes consist of 5 minutes of warming up, 20 minutes of exercise, and 5 minutes of cooling.

Subject has breathing exercises for manage the restrictive pulmonary problem, while

subject has not opportunity to examined the objective respiratory function by spirometry. Breathing exercise by diaphragmatic breathing and postural drainage supervised by a physical therapist for 30 minutes. We also gave education for the patient and caregivers about energy conservation techniques such as not to spend energy on things that are not important, planning activities and plan breaks before fatigue occurs, make a comfortable environment for activities and always use good posture to avoid fatigue.

Subject received chest expansion exercises using macrame as well as fine motor exercises to strengthen the muscles of the hand using putty, ADL exercise especially how to eat and drink more efficiently, and also writing exercises using a pen. Since the patient had ankle dorsiflexion weakness in both ankles, we recommended having bilateral ankle-foot orthosis.

Subject has medical social assessment by social worker officer related to the socio-economic condition, readiness for continue education, as well as the motivation for the sustainability of the rehabilitation program.

Other important education about precaution for the patient after surgery, includes avoiding any twisting, bending forward, heavy lifting, abdominal straining, prolonged sitting, and excessive physical activity were given. At the end the program, subject should walk, take stairs, lie down with proper back alignment, and have living areas arranged to prevent bending, stooping, and reaching. While changing body position, patients should use logrolling and transferring techniques learned in the inpatient setting.

Two months after program, subject was able to attend the junior high school near his house which can accommodate the needs and limitations of the patient including his difficulties using pen and writing. The patient was able to eat and drink independently, using a light plastic spoon and acrylic plate. Assessment of ADL by Modified WeeFIM score has found increasing of 113 the score, due to an improvement in eating. The evaluation of 2 Minute walking distance has shown 64 m of distance. These results were increasing. The design of safe and effective home-based rehabilitation program was need to subject, while doctor and therapist can monitor by video call, and evaluate once a month.

DISCUSSION

The aims of postoperative spine rehabilitation are to return to functional activities as soon and as safe as possible. The primary challenge is to restore the patient to full function as early as possible without compromising the integrity of surgical interventions.⁹ Since the patient has been already 3 months after surgery, the goal of this stage is to activate multi-muscle group starting from the deep muscles around the spine called core stabilization technique.⁵ The ability to control spinal segments during upright posture is required not only for activities of daily living but also for balance, stability, and coordination. It can be trained by drawing in maneuver which selectively co-activating and strengthen the transversus abdominis and multifidus muscles and lead to an improvement in anticipating postural strategies. The maneuver also increases intra-abdominal pressure by inwardly displacing the abdominal wall, therefore it is recommended for stabilization training.^{10,11}

Increasing subject knowledge about his condition by education was important role in rehabilitation assessment. It was important for subject to understanding that arthrodesis gradually over several months after surgery, so spinal fusion precaution should be taken.¹²

Severe scoliosis causes right and left posterolateral bulging of C7-T1 intervertebral discs which causes weakness especially in the intrinsic muscles of the hand, as well as posterocentral and left posterolateral bulging on the L4-L5 and L5-S1 intervertebral discs which cause bilateral drop foot. Base on this condition, long-term goal was need to increase strength for the upper and lower extremities. While, to strengthen and stabilize the lower extremities, subject has exercise in the pool, starting with strengthening exercise from hip to ankle. Exercise in pool has benefit in increasing ROM and reduce stiffness in the right knee. Bouyancy effect of water makes the patient easier to move. The hydrostatic pressure in water will also help to challenge balance and coordination when moving.¹³

Restrictive pulmonary problem in this case, manage by energy conservation techniques (activity simplification techniques) to reducing energy consumption and increasing efficiency in activity. The principle of simplification of activities includes 5 basic steps i.e planning daily activities, arrange daily and weekly activity plans, modification of activities, avoid unnecessary activities and analyze methods and steps when doing activities.¹⁴

Evaluation of EMG was need to determine the exact location of the lesion and excluded the differential diagnosis, i.e. myopathy. Creatine Phosphokinase (CPK) levels was necessary to examined. Further evaluation by pediatricians

was also necessary for echocardiography, to found cardiovascular related conditions due to severe scoliosis. Genetic counseling was important to exclude other rare syndromes that might be related to scoliosis with extremities weakness such as Spinal Muscular Atrophy, Neurodevelopmental disorders with or without hyperkinetic movements and seizures, Neurodevelopmental disorders with microcephaly, hypotonia, and variable brain anomalies, Potato-Grubbing Palsy, Lopes-Maciel-Rodan Syndrome, Pelizaeus-Merzbacher disease, or GM Gangliosidosis Type 3.¹⁵ A study conducted by Gao, et al mentioned the need for patients with unexplained early-onset scoliosis (EOS) to be screened using high-density microarray genotyping. This study revealed a genetic diagnosis of chromosome 15q24 microdeletion syndrome in 1 patient and maternal uniparental disomy of chromosome 14 in a second one. Prior genetic testing and clinical evaluations had been negative in both cases. A large novel chromosome 10 deletion was likely causal in a third EOS patient. These mutations identified in the EOS patients were absent in AIS patients and controls, and thus were not associated with AIS or found in asymptomatic individuals.¹⁶

CONCLUSION

Postoperative scoliosis rehabilitation programs consisting of strengthening exercises, ROM exercises, ADL exercises, and orthotic administration are proven to improve the functional abilities of patients. Severe scoliosis management requires collaboration between professions and interdisciplinary disciplines. It is also important to consider a safe and effective home exercise program model to accommodate patients who cannot attend training at the hospital routinely.

REFERENCES

1. Saul PM. Scoliosis and Other Spinal Deformities. In: *Delisa's Physical Medicine and Rehabilitation*. 5th ed, Frontera WR, Delisa JA, editors. Philadelphia: Lippincott Williams and Wilkins; 2010. p.883-903.
2. Dickson R. Epidemiology of Idiopathic scoliosis. In: *Idiopathic scoliosis*. 1st ed. Newton P, O'Brien M, Shufflebarger H, Bets R, Dickson R, Harms J, editors. New York: Thieme Medical Publishers, Inc; 2011. p.54.
3. Negrini S, Donzelli S, Aulisa AG, Czaprowski D, Schreiber S, Diers H, et al. 2016 SOSORT guidelines: orthopedic and rehabilitation treatment of idiopathic scoliosis during growth. *Scoliosis Spinal Disord*. 2018;13:3.
4. Helenius I, Mattila M, Jalanko T. Morbidity and radiographic outcomes of severe scoliosis of 90° or more: a comparison of hybrid with total pedicle screw instrumentation. *J Child Orthop*. 2014;8(4):345-52.
5. Canbulut N. Rehabilitation after surgery of the spinal deformity. *Turkish Neurosurgery*. 2014;24(1):107-14.
6. Solache-Carranco A, Sánchez-Bringas MG. Evaluation of a respiratory rehabilitation program in children with scoliosis. *Cirugia y Cirujanos*. 2012;80(1):11-7.
7. Sweeney L. Occupational therapy: Management of surgical and non-surgical spine. MiOTA-Spine-presentation_Oct_2019. Available from www.miota.org accessed on June 28 2020.

8. Ramirez JM, Eberson CP. The role of rehabilitation in the management of adolescent idiopathic scoliosis. *Pediatric Rehabilitation Medicine*. 2017: 22-4. Available from www.rimed.org accessed on June 28 2020.
9. Allen A, Zhu Z, Cho S.K. Adult and adolescent scoliosis. In: *Postoperative orthopedic rehabilitation*. 1st ed. Green A, Hayda R, Hecht A, editors. 1st ed. Philadelphia: Wolters Kluwer. 2018: 572-79.
10. Kisner C, Colby LA, Borstad J. *Therapeutic exercise: foundations and techniques*. 6th ed. Philadelphia: FA Davis Company; 2017: 511.
11. Hoogenboom B, Kiesel K. Core stabilization training. In: *Clinical orthopedic rehabilitation*. 3rd ed. Brontzman S.B, Manske R.C, editors. Philadelphia: Elsevier Mosby. 2011: 467.
12. Izu C, Plock H, Scott J, Slocar P, Cabalo A. Lumbar spine fusion. In: *Rehabilitation for postsurgical orthopedic patient*. 3rd ed. Maxey L, Magnusson J, editors. St. Louis Missouri: Elsevier Mosby. 2013: 329.
13. Cameron M.H, editor. *Physical agents in rehabilitation: from research to practice*. 4th ed. St. Louis Missouri: Elsevier. 2103: 323-26.
14. Watchie J. Cardiovascular and Pulmonary Physical Therapy: A Clinical manual. 2nd ed. St. Louis Missouri: Saunders; 2010.
15. Mendellian: Rare disease diagnosis, faster. <http://www.mendelian.co/symptoms/scoliosis-and-tetraparesis> accessed on June 28 2020.
16. Gao X, Gotway G, Rathjen K, Johnson C, Sparagana S, Wise CA. Genomic analysis of patients with unexplained early-onset scoliosis. *Spine Deformity*. 2014: 324-32.